

Performing a respiratory assessment

By Marjaana Mehta, MSN, RN, APN-C

A thorough respiratory assessment consists of inspection, palpation, percussion, and auscultation in conjunction with a comprehensive health history. Use a systematic approach and compare findings between left and right so the patient serves as his own control.

If possible, have him sit up. Uncover his chest and inspect the shape and configuration. Normally, the thorax is symmetrical and the anterior-posterior diameter is less than the transverse diameter. (Equal diameters may signal chronic obstructive pulmonary disease in an adult.) Note any structural deformity such as a pigeon chest (pectus carinatum) or funnel chest (pectus excavatum).

Note his breathing. Respirations should be even, unlabored, and regular at a rate of 12 to 20 breaths per minute. Normally, inspiration is half as long as expiration and chest expansion is symmetrical. If your patient appears anxious or exhibits nasal flaring, cyanosis of the lips and mouth, intercostal retraction, or use of accessory muscles of respiration, he may be in respiratory distress.

Starting your assessment on his back may help him relax. Proceed as shown in the following photos.







Starting at the back

1. Stand behind your patient and inspect his back for any deformities, such as kyphosis (convex curvature) or scoliosis (lateral curvature) of the spine. Next, gently palpate his back with your fingers, noting any tenderness, masses, lesions, temperature changes, or crepitus—a coarse, crackling sensation that's palpable over the skin. To test for symmetric chest expansion, place your thumbs at the level of the 10th ribs with your fingers loosely grasping and parallel to the lateral rib cage. Then slide them medially just enough to create a small skin fold between your thumbs, as shown. Ask him to inhale deeply and note if your thumbs move apart symmetrically as you feel for the range and symmetry of the rib cage as it expands and contracts.



2. Assess for tactile fremitus by placing the ball or the ulnar surface of your hands on the right and left sides of his upper back. Ask him to say "99" and note any absent or asymmetric increased or decreased palpable vibrations transmitted through the bronchopulmonary tree to the thorax as you move your hands down and from the center to the periphery.



3. To measure diaphragmatic excursion, ask your patient to inhale and hold it. Percuss from the lower edge of his right scapula down toward the diaphragm (see *Technique for percussion*). When the note changes from resonant to dull, you've located your first landmark. Tell him to breathe, then mark the landmark with a skin marker. Ask him to exhale and hold it, then repeat the process in full expiration. When the percussion note changes from resonant to dull, tell him to breathe. Mark this landmark.

Measure the distance between the marks to determine diaphragmatic excursion, normally 5 to 6 cm in adults. Repeat these steps on your patient's other side and compare. Because the diaphragm is usually higher on the right because of displacement by the liver, the measurement may be greater on the left.

Technique for percussion

For a right-handed nurse: Press the distal interphalangeal joint of your hyperextended left middle finger (the pleximeter) on the patient's skin. (Don't touch him with any other part of your hand, which could damp vibrations.) Next, position the partially flexed middle finger of your right hand (the plexor) very close above the distal interphalangeal joint of the pleximeter. Using your fingertip, not the pad, strike the pleximeter using a quick, sharp, relaxed wrist motion. Use the lightest percussion that produces a clear note and percuss twice in one location before proceeding. Percuss one side of the thorax and then the other. Omit the areas over the scapulae. Identify the area and quality of any abnormal percussion note.



4. Have your patient breathe deeply through his mouth. Using the diaphragm of your stethoscope, auscultate his lung sounds starting at the apices at C7 to the bases at approximately T10 and laterally from the axilla down to approximately the eighth rib. Decreased or absent lung sounds may indicate obstruction of the bronchial tree.

Listen for adventitious lung sounds. Crackles are distinct, noncontinuous sounds defined as "fine" (sound like popping) and "coarse" (sound like bubbling or gurgling and usually clear or decrease after coughing). Sibilant wheezes—high-pitched musical or whistling sounds—are commonly heard in patients with asthma, typically during or at the end of expiration. Sonorous wheezes, heard throughout inspiration and expiration, may be caused by airway secretions or bronchoconstriction.

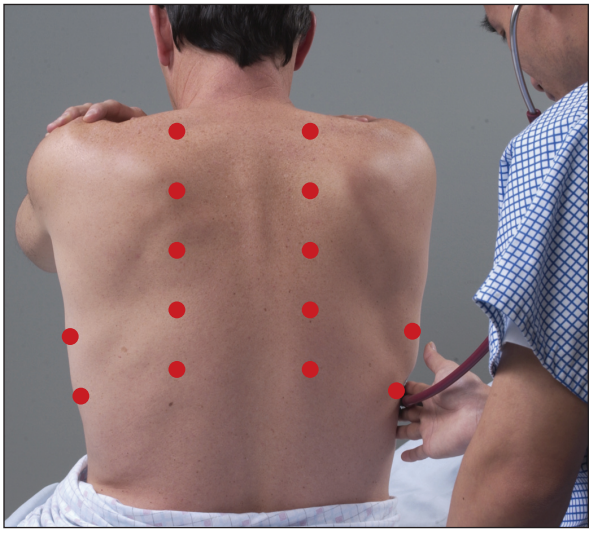

Up-front assessments

5. Have your patient lie supine, and percuss his anterior and lateral chest as shown. (Percuss the areas of auscultation shown in step 6.) Use a systematic approach and compare resonance from one side to the other. Dullness over the diaphragm, liver, and other visceral organs is normal but over the lungs may indicate a mass or consolidation. Hyperresonance over the lungs indicates hyperinflation. You'll note flatness over muscle or bone.



6. If possible, have your patient sit up and breathe deeply through his mouth. Place the diaphragm of your stethoscope above the supraclavicular notch and medial to the cricoid cartilage. Auscultate his breath sounds at the areas indicated, down to the sixth rib.

- Tracheal sounds, heard over the trachea in the neck, are relatively high-pitched, and very loud with inspiration and expiration of equal duration.
- Bronchial sounds are heard over the manubrium, if present. They're loud and relatively high-pitched, with expiration sounding slightly longer than inspiration.
- Bronchovesicular sounds are audible in the first and second interspaces anteriorly and between the scapulae. The sounds of inspiration and expiration are equally long.
- Vesicular sounds, heard over most of the lung fields, are soft, relatively low-pitched. Inspiratory sounds last longer than expiratory sounds.

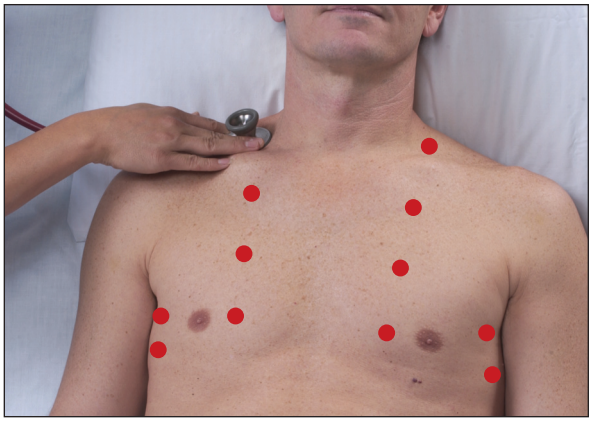

RESOURCES

Bickley L. *Bates Guide to Physical Examination and History Taking,* 10th ed. Philadelphia, Pa., Lippincott Williams & Wilkins, 2008.

Jarvis C. *Physical Examination and Health Assessment,* 3rd ed. Philadelphia, Pa., W.B. Saunders Co., 2000.

Marjaana Mehta is an advanced practice nurse in adult medical oncology at Hackensack (N.J.) University Medical Center.